

# The No Scalpel Vasectomy (NSV) Office based procedure

Review of 190 vasectomies in rural procedural general practice

by Dr Mark Elvy

## Background

*Vasectomy is one of the safest and most effective methods of permanent birth control. It is much safer and less expensive than other common contraceptive surgery such as tubal ligation. For these reasons, some 29,000 men<sup>1</sup> in Australia choose vasectomy each year.*

*Cost effectiveness of minor surgical procedures has become an important issue to authorities with limited health dollar. The cost of vasectomy in the public health system has been estimated by some<sup>2</sup> to be around \$2000.*

*Hence, with a cost to Medicare of \$180, including consultation<sup>3</sup>, the NSV as an office-based procedure may be a financially attractive alternative. Ironically, in the private system, the day surgery vasectomy may be more cost effective for the actual patient.*

## Objective

*To assess the safety profile and where possible the effectiveness at 3 months of the No Scalpel Vasectomy<sup>4</sup> (also known as Li Vasectomy) as an office based procedure in rural general practice.*

## Method

*One hundred and ninety patients were reviewed to assess age at operation, number of children; complication rates; and efficiency of the Li Vasectomy. Follow-up rates and sperm analysis were reviewed at 3 months.*

## Results

- *The average age for vasectomy was 41 years with 55 % of patients between 36 and 45*
- *The mean number of children was 2*
- *Documented complication rates were acceptable with no serious or long-term problems*
- *The commonest complication was congestive epididymo-orchitis with a rate of 4.1%*
- *Wound infection rate was zero*
- *40 % of patients failed to have post-vasectomy sperm analysis*

## Conclusion

*Non Scalpel Vasectomy is a safe, effective, inexpensive procedure. It is well tolerated by patients and has a low complication rate with very low failure rate*

## Introduction

Conventional vasectomy blocks the vas deferens preventing sperm from being added to semen. A general anaesthetic or local anaesthetic (patient's or operator's preference) is given, and one or two incisions are made in the scrotum with a scalpel. The vas deferens are revealed, cut and blocked (suture ligation, clips or diathermy to both proximal and distal ends). The incisions are then closed with sutures.

A less invasive procedure, the No Scalpel Vasectomy (NSV) reduces vasectomy's already low complication rate. Developed in China by Dr Li in 1974, it differs from conventional vasectomy in how anaesthesia is given and in how the two vasa are reached. Worldwide

more than 15 million men have had this procedure.

A comparative study of the no scalpel and standard incision approaches to vasectomy in five countries concluded that the no scalpel approach is an important advance in the surgical approach to vasectomy, and offers fewer side effects and greater comfort compared to the standard incision technique, without compromising efficacy<sup>5</sup>

Preoperatively patients and partners are counselled re suitability and permanence of vasectomy. Technique and complications (including failure rate) with my personal rate of complications discussed. Fully informed consent is obtained in writing. A "cool off"

period of 7 days is usual before the procedure is undertaken. One week pre-op Sapoderm soap is used and 12 hours pre-op oral Keflex is administered and continued for 48 hours. The operator performs a peno-scrotal junction shave at the time of vasectomy, taking care to avoid patient "nicks".

No Scalpel Vasectomy uses a peri-vas local anaesthetic (Marcaine or Xylocaine without adrenaline) technique to anaesthetise the operation field effectively without distorting the anatomy with local anaesthetic volume.

This is important as the "Li 3 finger technique" relies on feel and localisation of the vasa.

The vasa is isolated and brought to the surface allowing it to be fixed with a Li clamp. This clamp will hold scrotal skin, dartos muscle, and the coverings of the vas deferens<sup>6</sup> (external spermatic fascia, cremasteric fascia and internal spermatic fascia).

A small stab is made above the “fixed vasa” and a small tear is made (3 to 4 mm). The coverings of the vasa are dissected and “brushed” off. Peri-vas blood vessels may bleed at this point and are treated with localised diathermy or ligation. The vasa is delivered through the small tear and ligated with the proximal end tied, clipped or diathermied. The distal end is left opened (to reduce congestion syndrome) and a pouch is made from fascial remnants to “bury” it from the proximal end. Studies have indicated that apart from excisions of long segments (>4cm) of vasa, this technique has the lowest failure rate of between .02% and 0.24% <sup>7</sup>. The other side is treated the same way through the initial tear. No closure of the scrotal skin is required.

A small waterproof dressing is applied and the patients given a stat dose of 400mg of Celebrex and Tramal 50. Panadeine is given to the patient to be used PRN. The office-based patients may drive home and are advised to take it easy for several days (this review indicates bleeding can occur day 2 or 3 following excessive physical activity). Normal showering is possible but swimming should be avoided for 7 days.

Patients require one (clerical) to four (heavy physical) days off work. Thursday or Friday are popular with patients, with return to work on Monday. Abstinence from sexual activity is required for one week, following this frequent ejaculations are encouraged (at least 20 in 3 months). Contraception must be maintained until the result of the semen analysis is known.

**Semen analysis at 3 months**

Nil Spermatozoa

Non Viable occasional Spermatozoa

2nd Test Non Viable occasional spermatozoa

2nd Test Nil Spermatozoa

Normal result

**Action**

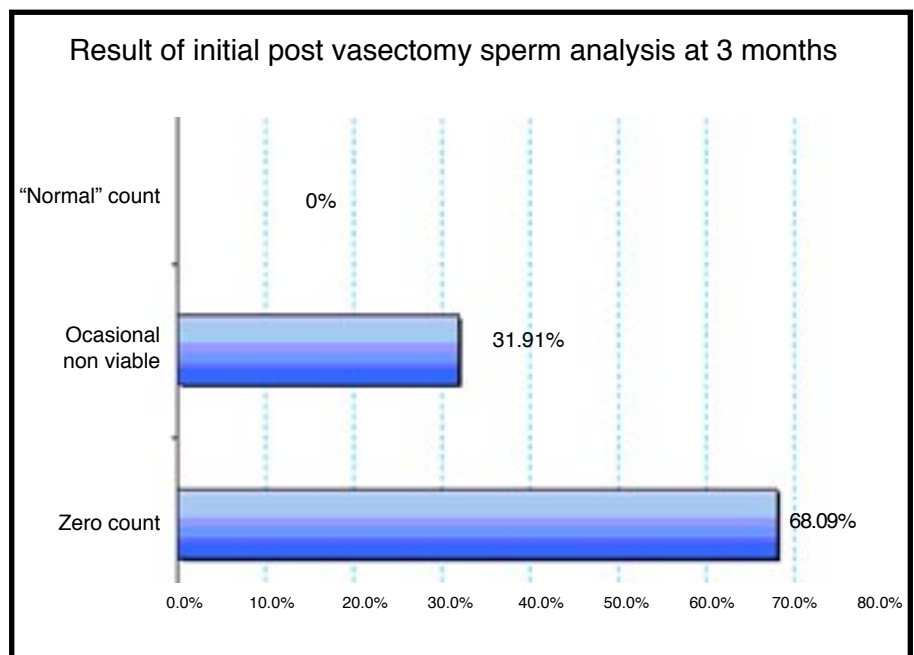
Letter written advising operation successful and cessation of previous contraception

Maintain contraception and repeat sperm test in one month

Letter written advising operation successful and cessation of previous contraception

Letter written advising operation successful and cessation of previous contraception

See patient and advise failure and discuss options



Patients are given the operator’s mobile number and advised to make contact if there are problems or concerns.

At three months a semen analysis test (with instructions) is ordered and result sent to their local doctor

**Indications for non-scalpel vasectomy**

- Fully informed patient (and partner) having completed their family wishing a permanent, safe, convenient, cost effective form of contraception with very low failure rate

**Contra-indications**

- Local infection
- Recent trauma
- Anatomical abnormalities (hernia, inability to palpate both vas due to congenital absence or distortion of anatomy due to large varicoceles, hydroceles or immobility of vas)
- Emotional instability

## Complications

Possible complications can be divided into four categories:

### Pre operative

- Vasovagal reactions
- Anxiety reactions
- Drug allergies and side effects

### Intraoperative

- Intravascular injection of LA (*Adrenaline containing anaesthetic agents should be avoided*)
- Haematoma from LA and dissection
- Damage to testicular vessels and nerves

### Early postoperative

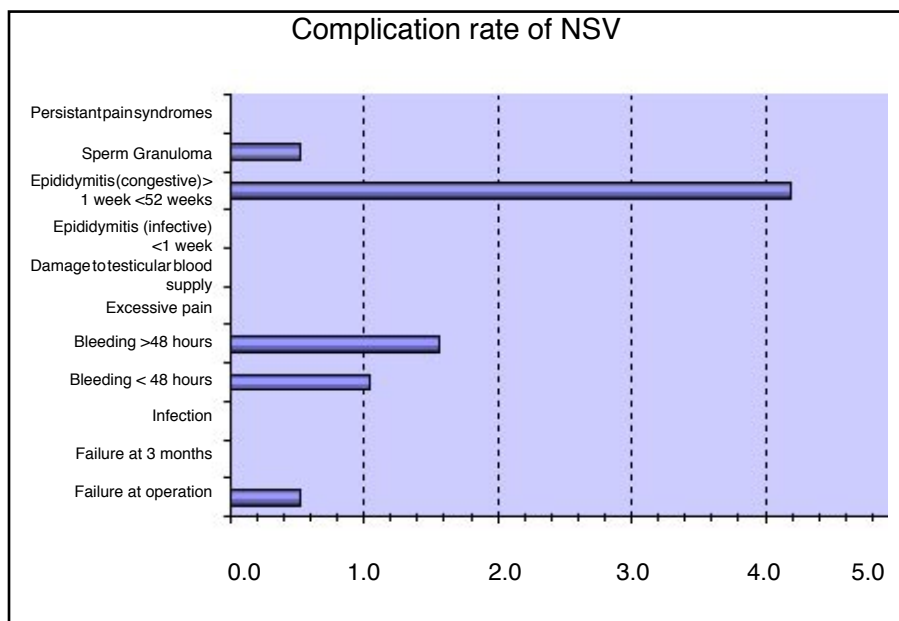
- Haematoma
- Wound infection
- Epididymitis and/or orchitis
- Excessive pain

### Late postoperative

- Congestive epididymitis and/or orchitis
- Sperm Granuloma
- Persistent pain syndromes

## Discussion

The average age for vasectomy was 41 years with 55 % of patients between 36 and 45. Most couples had considered vasectomy as a permanent form of contraception for at least 6 months. Interestingly, 11%



were 50 years or older.

Two patients out of 190 were noted to have only one vas on initial assessment. These patients had investigations (Ultrasound). Of these, one had absence of ipsilateral kidney, ureter and epididymis, and one had normal anatomy. These patients had unilateral vasectomy and both showed nil spermatozoa at 3 months

Two patients were unable to be successfully vasectomized at the initial procedure under LA, one due to technical error (loss of cut vas into scrotum) and one due to poor patient selection (moderate varicocele). These required general anaesthetics and formal vasectomy.

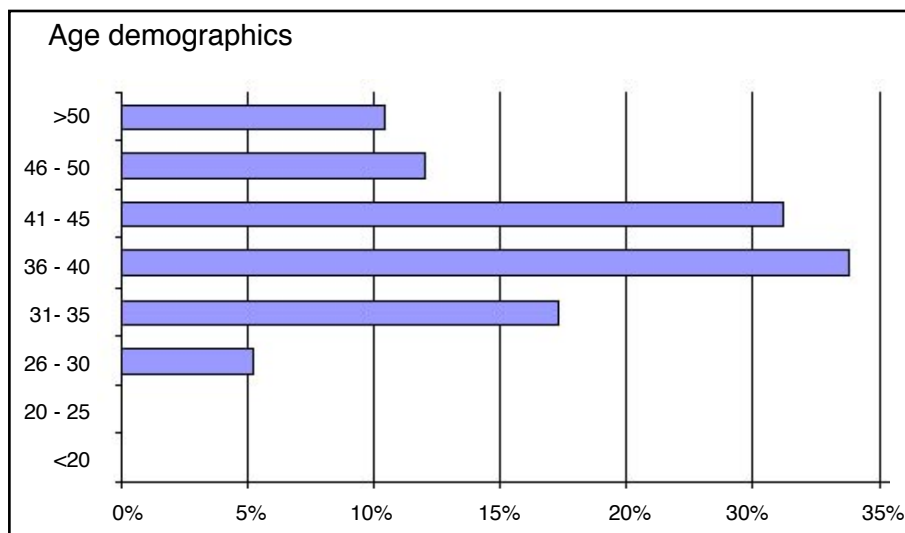
One hundred and eighty eight out of 190 were successfully completed procedures, of which, there were no documented failures at 3 months.

Some authorities<sup>8</sup> consider semen analysis at 10 weeks showing no living spermatozoa as proof of post vasectomy sterility. However, this author was more conservative with his approach and followed the previous flow chart.

Of considerable interest was the poor compliance rate of follow up sperm analysis at 3 months. 40 % of patients failed to have post vasectomy sperm analysis. Of those that showed “occasional non viable sperm” nearly half did not follow up with a second sperm analysis.

The commonest complication (4%) was an episode of unilateral epididymitis and or orchitis between one week and 52 weeks following procedure. As this complication was mainly seen around 1 to 3 months, its incidence may be underestimated as patients could have presented to their family physicians or after-hours service. Several local medical officers have been kind enough to notify me of this complication to allow accurate documentation.

This complication has been termed “Congestive epididymitis and/or orchitis” and its exact cause is not



known. Treatment with NSAIDs and antibiotics is effective.

Bleeding was the next commonest complication, 1% within 48 hours and 1% greater than 48 hours. Bleeding at greater than 48 hours was only noted in patients with physical occupations and often related to an incident (fall off a ladder, lifting heavy object at work). All these patients recovered with conservative management with no long-term sequelae.

The infection rate was zero.

There were no serious complications from No Scalpel Vasectomy (NSV)

#### Conclusion

Non Scalpel Vasectomy is a safe, effective, inexpensive procedure. It

is well tolerated by patients and has a low complication rate with very low failure rate.

Office based Li Vasectomy should be considered as an alternative to standard vasectomy under general anaesthetic.

Public Hospital administrators should consider the cost effectiveness of Office based Non Scalpel Vasectomy (NSV) .

#### Endnotes

<sup>1</sup> HIC web site inquiry for item 37622,37623

<sup>2</sup> Personal discussion with administrators MNCAHS

<sup>3</sup> Medicare benefits Schedule Book 1 Nov 2002

<sup>4</sup> Li S, Goldstein M Zhu Jet al: the no scalpel vasectomy J urology 145:341-344,1991

<sup>5</sup> A comparative study of the no scalpel and standard incision approaches to vasectomy in 5 countries. The Male Sterilization Investigator Team J Urol, 162(5): 1621-5 1999

<sup>6</sup> Moore K, Clinically orientated Anatomy 2<sup>nd</sup> Ed page 182

<sup>7</sup> Davis L, Stockton M No Scalpel Vasectomy Primary Care Volume 24 number 2 June 1997 433-454

<sup>8</sup> A comparative study of the no scalpel and standard incision approaches to vasectomy in 5 countries. The Male Sterilization Investigator Team J Urol, 162(5): 1621-5 1999